

# Ovarian dehydrogenases of the non-pregnant, pregnant and lactating *Rhinopoma microphyllum kinneari* (Chiroptera: Rhinopomatidae)

Seema TRIVEDI\* & S. B. LALL

\*Department of Zoology, J. N. Vyas University, Jodhpur (Rajasthan), India  
Department of Zoology, ML Sukhaida University, Udaipur (Rajasthan), India

**Abstract.** *Rhinopoma microphyllum kinneari* is an insectivorous microchiropteran, breeding once in a year. Histochemical localisation of two dehydrogenases viz., succinate dehydrogenase (SDH) and lactate dehydrogenase (LDH), was achieved in the ovaries of bats obtained during non-pregnant, pregnant and lactating stages. Differential enzyme activities in different structures of the ovaries were visually evaluated. Reproductive stage specific changes in the profiles of the enzymes were observed. In the non-pregnant bats, both SDH and LDH showed high staining profile in the ovaries of the two sides. In the pregnant bats, the ovary bearing the corpus luteum had moderate SDH and LDH reaction while the non-ovulating ovary had lower SDH and LDH staining reaction. In the contralateral ovaries of the lactating bats, both the SDH and LDH profiles were very low.

**Succinate dehydrogenase, lactate dehydrogenase, ovary, corpus luteum, *Rhinopoma***

## Introduction

Dehydrogenases of the glycolytic and tricarboxylic acid (TCA = Krebs Cycle) pathways play an important role in providing energy needed for various metabolic activities of somatic and germ cells. An essential enzyme of the TCA cycle, succinate dehydrogenase (SDH) and an enzyme of the glycolytic pathway, lactate dehydrogenase (LDH), were chosen for the present study to monitor their histochemical shift in different reproductive stages. The aforesaid enzymes were chosen mainly because they play important roles in carbohydrate metabolism and would serve as indicators of the energy requirement for folliculogenesis. The activity of these enzymes may vary in the process of follicle maturation (Bjersing 1977, Guraya 1985).

Chiropterans are enigmatic animals as they are not only the true flying mammals, but also have diverse reproductive patterns (Wimsatt 1979). *Rhinopoma* breeds once each year and possesses ovaries which function alternately in each cycle (Anand Kumar 1965, Lall 1986, Trivedi 1991). Very few studies regarding histochemical localisation of dehydrogenases in chiropteran ovaries have been carried out (Jaroli 1980). SDH and LDH have been localised in the ovaries of rodents, lagomorphs, ungulates, primates and some species of bats (species not mentioned in the text of the book) (Bjersing 1977, Guraya 1985).

## Materials and Methods

*Rhinopoma microphyllum kinneari* females were collected from roosting sites when they were in either non-pregnant, pregnant (early pregnancy) or lactating (within a week after parturition) stages. Five bats from each stage were sacrificed and their ovaries were removed and weighed individually. Fresh frozen sections (7–10 mm thickness; obtained by cryostat sectioning) of all the ovaries (of both sides) from each bat were incubated in substrate media (di-sodium succinate for SDH and sodium-DL-lactate for LDH) as follows:

The technique of Nachlas et al. (1957) for SDH and of Hess et al. (1958) for LDH were used as cited in Pearse (1972). Appropriate controls were run in substrate deficient media. The reaction product [formazone granules: purple colour due to transfer of electron to Nitro Blue Tetrazolium (NBT) as a result of enzyme reactions] colour intensity was visually scored as follows: +++ = strong; ++ = moderate; + = low; - = negligible; -- = no reaction product; (G) = granulosa cells; (T) = thecal cells. For comparison of reaction intensity in all components of ovary of each reproductive stage following symbols have been used: ↑↑ = strong; ↑↑ = <strong; ↑ = moderate; ↓ = low; ↓ = negligible

## Results

Succinate dehydrogenase and lactate dehydrogenase were localised in the ovaries of non-pregnant, pregnant and lactating bats. The profile of each enzyme in the different reproductive states follows.

### SDH

In the non-pregnant state of *Rhinopoma*, follicles in the ovary of *Rhinopoma* had low (+) to moderate (++) enzyme profile. High (+++) reaction product pockets were seen in the stroma. The granulosa cells had higher SDH reaction. The thecal cells had either no SDH reaction or was very low and low enzyme activity was seen in ooplasm (Tab. 1). Granulosa cells of secondary follicles had moderate to high enzyme activity (Fig. 1). The enzyme profile in the other ovary was not significantly different (Fig. 2). Some primary and secondary follicles had low enzyme activity in granulosa and thecal cells as compared to other similar follicles. However, in such follicles the thecal cells showed higher activity as compared to the granulosa cells Antral follicles had differential high to moderate enzyme reaction product in their granulosa cells. (Tab. 1).

In pregnant bats, the ovary bearing the corpus luteum, SDH reaction product staining in follicles was either not present (--) or was negligibly low (-) (Tab. 1). The corpus luteum had moderate SDH reaction (Fig. 3). The non-ovulating ovaries of pregnant bats had very low enzyme activity in all follicle types. The stroma was devoid (--) of any reaction (Tab. 1). A comparison of the two ovaries of pregnant bats reveals no significant difference in the enzyme profile of the follicles specially the primary follicles. However, on taking corpus luteum into account, the ovary bearing the corpus luteum shows higher SDH profile as compared to the contralateral ovary not bearing corpus luteum (Tab. 1).

In lactating bats, ovary of one side (Fig. 4) manifested no (--) SDH reaction in the oocytes. Some primary follicles showed scant reaction. Ooplasm of the healthy follicles had low (+) reaction. The reaction was confined generally to the granulosa cells only. Stroma had low reaction and had pockets of mild SDH activity. The primary and secondary follicles in the contralateral ovary (Fig. 5) of lactating bats had the same enzyme profile as the other ovary. However, the granulosa cells of tertiary and pre-antral follicles had moderate SDH reaction. In such follicles, the thecal and granulosa cells did not show any difference in the enzyme profile. Stroma region had few pockets of intense SDH reaction (Tabs. 1 and 3). On comparing the contralateral differences, it was seen that in ovary of one side the secondary and tertiary follicles had lower SDH activity and the stroma had higher reaction profile as compared to the other ovary (Tab. 1).

A comparison of the ovaries of the three reproductive states reveals that the non-pregnant phase showed highest reaction product staining of SDH activity. The pregnant phase had moderate reaction, on considering the corpus luteum in the overall profile, otherwise the follicles had very low SDH activity. The lactation state had the lowest SDH activity (Tabs. 1 and 3).

### LDH

The lactate dehydrogenase profile in the contralateral ovaries of the three reproductive states is as follows:

Tab. 1. SDH profile in the ovaries of *Rhinopoma microphyllum kineari*

Tab. 1. Profil sukcinat-dehydrogenasy (SDH) vaječnicků víkonosa velkého (*Rhinopoma microphyllum kineari*)

follicle type	non-pregnant		pregnant		lactating	
	left	right	ovulating side	non-ovulating side	left (Fig. 4)	right (Fig. 5)
oocytes	++	+ to ++ (Fig. 2)	- to --	-	--	--
primary follicles	+ to ++	+ to ++ (Fig. 2)	-	+	--	--
secondary follicles	++ to +++ (Fig. 1)	+ to ++	+	+	- +	- to +
tertiary follicles	+ to +++	+	+	+	+	+ to ++
pre-antral follicles		+				++
antral follicles	++ to +++	+ to +++ (Fig. 2)			+	++
ooplasm	+	+	+	+	+	++
stroma	++ to +++	+++ (Fig. 2)	-	-	+	++
corpus luteum			+ to ++ (Fig. 3)			

In the ovary of one side of the non-pregnant phase (Figs. 6 and 7 and Tab. 2), moderate to high (++ to +++) lactate dehydrogenase activity was seen in all the components. Ooplasm of healthy follicles had scant LDH activity. Thecal cells lacked any LDH activity. Stroma had pockets of moderate enzyme reaction product staining. The contralateral ovary did not differ significantly in manifesting the LDH activity (Tab. 2).

In the pregnant phase, the ovary bearing the corpus luteum manifested low to negligible (+ to --) LDH activity in all the follicle types in granulosa and thecal cells. The corpus luteum displayed moderate enzyme profile (Fig. 8). The non-ovulating ovary of the pregnant bats did not show any significant variations in the LDH activity (Tab. 2). Contralateral differences in the two ovaries of the pregnant bat are significant only when considering the enzyme activity manifested in the lutein cells. In this case the ovary bearing the corpus luteum has higher LDH activity as compared to the contralateral ovary.

In lactating bats, ovary of one side (Fig. 9) displayed low to negligible (+ to --) enzyme activity in all follicle types. Antral follicles had elevated LDH reaction in the contralateral ovary (Fig. 10) of the lactating bats. Secondary follicles had moderate profile. Primary follicles had either no reaction or scant activity. Generally granulosa cells manifested enzyme reaction as compared to the thecal cells in most of the follicle types. However, in some secondary follicles the thecal cells were LDH positive. Ooplasm of healthy follicles showed some reaction. Stroma had pockets of high enzyme activity (Tab. 2). A comparison of the two ovaries of the lactation phase indicates contralateral differences in the LDH profile. Ovary of one side had negligible or very weak reaction whereas the contralateral ovary had some enzyme activity (Tabs. 2 and 3).

The three reproductive states displayed differential LDH reaction profile. The non-pregnant phase showed high LDH staining reaction. The pregnant phase had moderate profile if the LDH activity of the lutein cells is taken into account, else the follicle types had very low reaction

Tab. 2. LDH profile in the ovaries of *Rhinopoma microphyllum kineari*

Tab. 2. Profil laktat-dehydrogenasy (LDH) vaječníků víkonosa velkého (*Rhinopoma microphyllum kineari*)

follicle type	non-pregnant		pregnant		lactating	
	left	right	ovulating side	non-ovulating side	left (Fig. 9)	right (Fig. 10)
oocytes	+	+	- to --	- to --	--	-- +
	(Fig. 6)	(Fig. 2)				
primary follicles	+	++	- to --	- to --	- to --	- to +
	(Figs. 6, 7)	(Fig. 2)				
secondary follicles	++	++	+	+	- to +	+ to ++
	(Fig. 6)					
tertiary follicles	+++ to +++ (G)	+++ to +++ (G)			+	+
	-- (T)	-- (T)				
pre-antral follicles	+++ to +++ (G)	+++ to +++ (G)				++
	-- (T)	-- (T)				
antral follicles	++ to +++ (G)	+++ to +++ (G)				+++
	-- (T)	-- (T)				
	(Fig. 6)	(Fig. 2)				
ooplasm	+	++	-	-	+	+ to ++
	(Fig. 6)					
stroma	+ to +++	+ to ++	-	-	+ to ++	+
	(Figs. 6, 7)	(Fig. 2)				
corpus luteum			++			
			(Fig. 8)			

staining. The lactation phase had low to negligible reaction staining (Tab. 3). Comparison of SDH profile with LDH profile in all three reproductive states (Tab. 3) shows no significant difference in the profile of the two enzymes.

## Discussion

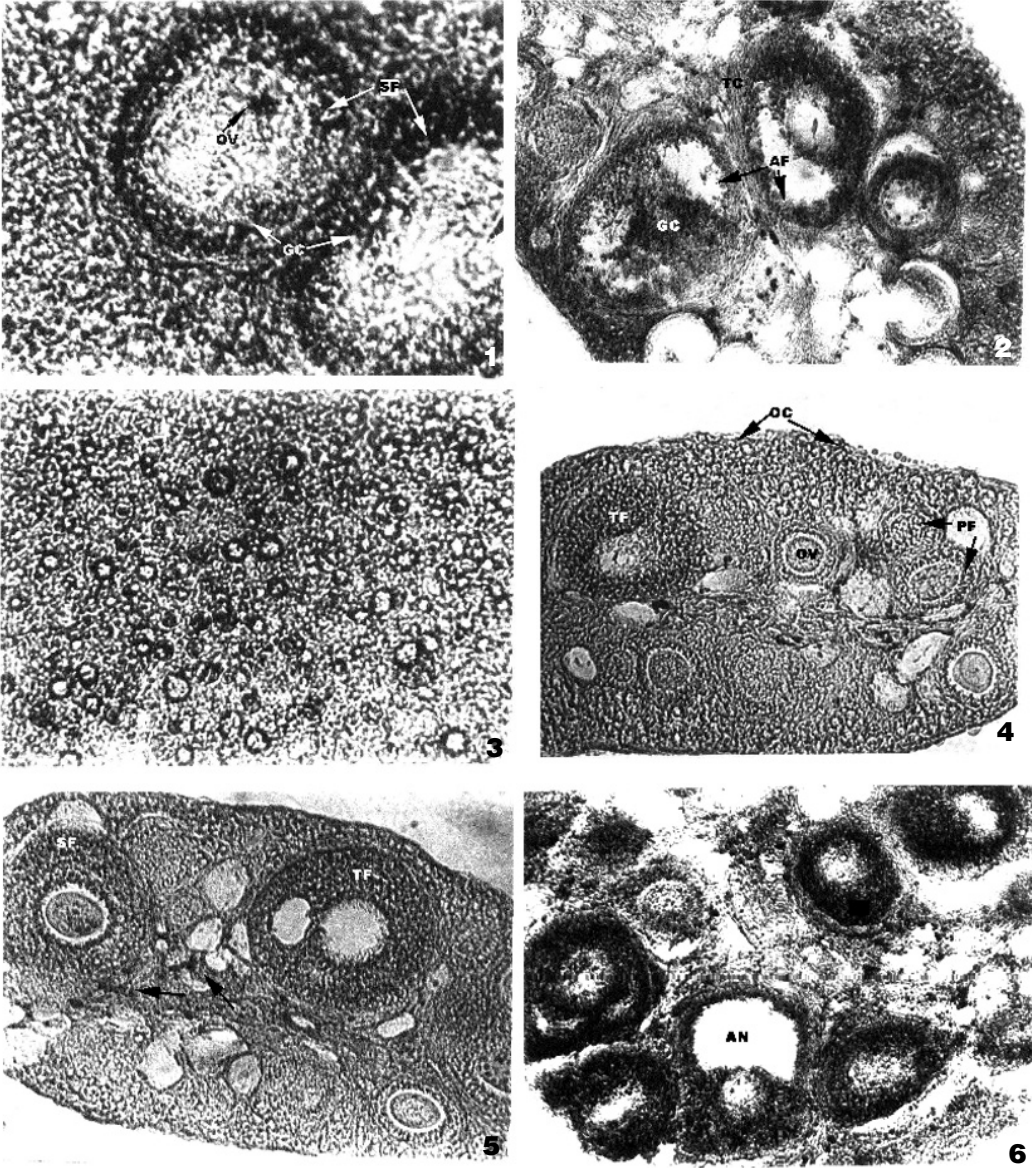
Our results indicate changes in the histochemical profiles of succinate dehydrogenase and lactate dehydrogenase activity during different reproductive states of the bat. Differential staining patterns were observed in the various follicles, granulosa, thecal and stroma cells.

Jaroli (1980) studied the histochemical profile of SDH in the non-pregnant and pregnant *Taphozous melanopogon melanopogon*. Considerable variation in the enzyme activity in different follicle types and contralateral differences were also observed as this bat has dextral dominance of ovarian function. In non-pregnant *T. m. melanopogon*, intense SDH reaction products were seen in granulosa cells of primary, pre-antral and antral follicles. The staining intensity was also

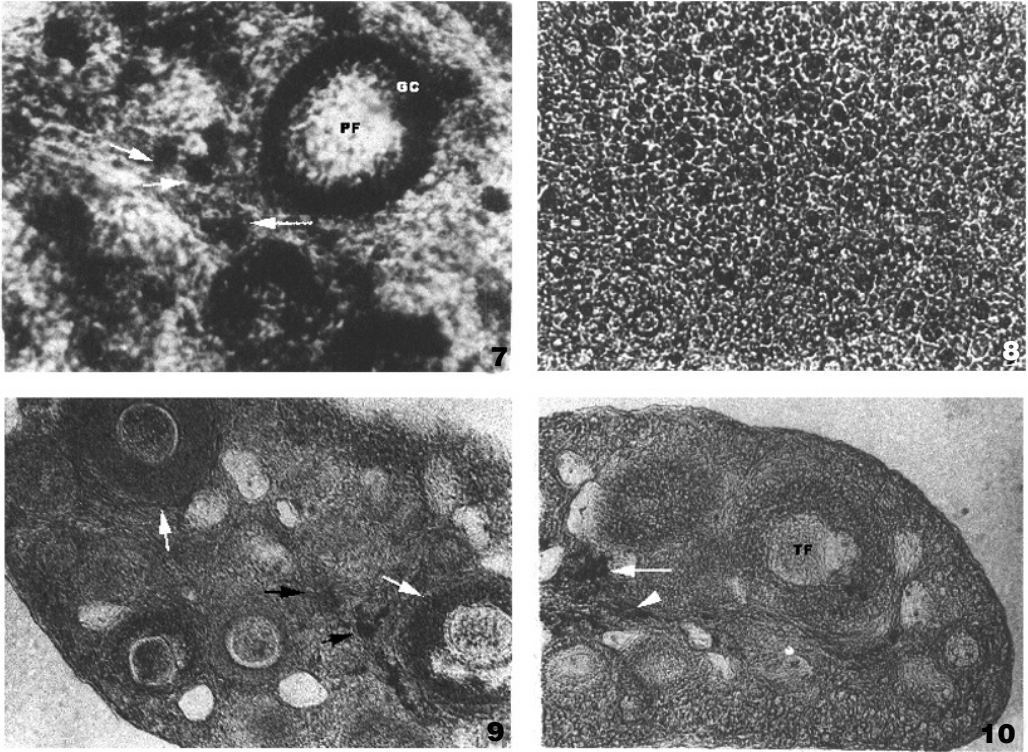
Tab. 3. Comparison of SDH and LDH activity in the ovaries of *Rhinopoma microphyllum kineari*

Tab. 3. Porovnání aktivity SDH a LDH ve vaječnicích víkonosa velkého (*Rhinopoma microphyllum kineari*)

enzyme	non-pregnant phase		pregnant phase		lactation phase	
	left ovary	right ovary	ovulating side	non-ovulating side	left ovary	right ovary
SDH	↑↑	↑↑	↑	↓	↓	↓
LDH	↑↑	↑↑	↑	↓	↓	↓



Figs. 1-6. Fig. 1. Primary follicles of non-pregnant ovary showing SDH activity in granulosa cells. Low intensity of enzyme products can be seen in the ovary ( $\times 40$ ). Fig. 2. Differential intensity of enzyme reaction product is seen in granulosa cells and thecal cells of antral follicles ( $\times 10$ ). Fig. 3. Lutein cells of pregnant bat displaying SDH activity ( $\times 10$ ). Fig. 4. Oocytes and Primary follicles displaying low enzyme reaction product intensity. Tertiary follicles having moderate enzyme reaction ( $\times 10$ ). Fig. 5. Secondary follicles displaying moderate and tertiary follicles higher enzyme activity ( $\times 10$ ). Fig. 6. Different follicle types displaying intense LDH reaction in the granulosa cells ( $\times 10$ ). Legend: OC = oocytes, PF = primary follicle, SF= secondary follicle, TF = tertiary follicle, TC = thecal cells, GC = granulosa cells, OV = OVA, AN = antral follicle.



Figs. 7–10. Fig. 7. Primary follicle granulosa cells and pockets (arrows) in the stroma region displaying intense LDH reaction product intensity ( $\times 40$ ). Fig. 8. Lutein cells with LDH activity ( $\times 10$ ). Fig. 9. Thecal cells (white arrows) displaying differential LDH activity. Stroma region having pockets (black arrows) LDH reaction product ( $\times 10$ ). Fig. 10. Stroma region having pockets (white arrows) LDH reaction product ( $\times 10$ ). Legend: see Figs. 1–6.

high in the thecal cells, cumulus oophorus and stroma. Atretic follicles also had elevated reaction. In pregnant bats the ovary bearing the corpus luteum had intense SDH reaction product specially in the lutein cells. Atretic follicles and interstitial tissue also had elevated SDH reaction product. Differential SDH reaction intensity has been found in *R. m. kinneari* in the present study. Studies on other species of bats has not been reported except a brief mention of these studies in some bats (species not mentioned) by Guraya (1985).

SDH has also been demonstrated histochemically in ovaries of Guinea pig, rat, rabbit, dog, cow, pig, and man (Bjersing 1977). In different follicles and corpus luteum of other mammals increase in the enzyme activity is proportional to follicular growth and highest profile in the pre-ovulatory oocytes has been reported. However, low SDH activity in theca cells of normal growing and antral follicles of goat ovary has been found (Guraya 1985). In rat ovaries, intense SDH activity has been reported in the granulosa cells of tertiary follicles as well as in the corpus luteum, theca interna and interstitial cells. Increased enzyme activity has been reported in the ovaries of parturient rats. SDH activity in the ovaries of guinea-pigs was similar to that in the rat ovaries (Bjersing 1977). Pig ovarian follicles and interstitial tissue have been found to be

SDH positive. Interstitial tissue have higher SDH profile than the follicles (Mayner 1966). SDH profiles in rat and pig are similar to those reported in rabbit and man (Hadjiisky et al. 1969). Thus, with the changing reproductive stages the profile of SDH activity changes in mammals including *Rhinopoma*.

LDH has been histochemically demonstrated in the growing oocytes, and theca interna in the ovaries of rat, rabbit, man and other mammals. LDH activity has been found to be directly proportional to the size of the growing follicle. Lower activities are however seen in the pre-implantation ova (Bratt et al. 1968, Bjersing 1977, Hadjiisky et al. 1969, Guraya 1985). Granulosa cells of nonovulatory tertiary follicles in human ovary show moderate LDH activity. Histochemical changes LDH profile in the granulosa cell layers of growing follicles of Indian gerbil have been observed (Guraya 1985). The differential staining in the granulosa cells of a single follicle reported in this study has not been found in *R. m. kinneari* ovaries however, increase in LDH activity with increase in follicle size was observed. This would imply increase in carbohydrate metabolism by the growing follicles. Histochemical shifts and localization that have been found in the present study are similar to *T. m. melanopogon* (Jaroli 1980) non-pregnant state ovary in which intense LDH reaction product in the granulosa cells of primary, pre-antral and antral follicles has been reported. Intense reaction product has also been reported in thecal cells, cumulus oophorous, stroma and atretic follicles. Liquor folliculi was also LDH positive. These studies indicate that the ovary of these species possess enzymes for the glycolytic pathway which seem to be "switched on" under oxygen-deficient conditions. Further, lactates seem to be utilized as readily metabolizable substrates.

SDH and LDH profiles reported in ovaries of *T. m. melanopogon* during different reproductive stages were similar to *Rhinopoma* though *T. m. melanopogon* has ovarian functional asymmetry having dextral dominance of the ovary and *Rhinopoma* has functional equivalence of the genital tract. From the present study it appears that succinate dehydrogenase and lactate dehydrogenase are involved in cyclic ovarian function. The differential pattern indicates altered metabolic demands during different reproductive states. However, there was no significant difference in the profile of SDH with that of LDH profile in all the three reproductive stages. This may be because of equal contribution of glycolytic pathway and Krebs Cycle for providing energy for the reproductive functions.

## Souhrn

**Ovariální dehydrogenasa negravidních, gravidních a laktujících samic víkonosa velkého (*Rhinopoma microphyllum kinneari*) (Chiroptera: Rhinopomatidae).** Víkonos velký (*Rhinopoma microphyllum kinneari*) je hmyzožravý netopýr rozmnožující se jedenkrát ročně. Ve vaječnicích samic tohoto netopýra byla histochemicky šetřena přítomnost dvou enzymů – dehydrogenas – totiž sukcinát dehydrogenasy (SDH) a laktát dehydrogenasy (LDH), a to v průběhu gravidity, laktace a v negravidním stadiu. V různých částech vaječnicků byla visuelně hodnocena aktivita různých enzymů a byly pozorovány specifické změny v profilech obou enzymů v jednotlivých reprodukčních stadiích. U negravidních samic SDH i LDH vykazovaly vysoký barvicí profil ve vaječnicích obou stran. U gravidních samic měly vaječnický, nesoucí žluté tělíčko, mírnou SDH a LDH reakci, zatímco neovulující vaječnický měly nízkou reakci obou enzymů. Vaječnický laktujících samic měly velmi nízký profil jak SDH, tak i LDH.

## Acknowledgements

We are thankful to U. G. C. (University Grants Commission, India) for the financial assistance for the study and to Mr. Abhay Pendse for his help with photographs.

## References

- ANAND KUMAR T. C., 1965: Reproduction in the rat-tailed bat *Rhinopoma kinneari*. *J. Zool. Lond.*, **147**: 147–155.
- BIERSING L., 1977. Ovarian Histochemistry Pp. 303–391. In: ZUKERMAN L. & WEIR B. (eds.): *The Ovary. Vol. I. Second edition*. Academic Press, New York, 517 pp.
- BRAIT H., PUPKIN M., LLOYD C. W., WEISZ J. & BALOGH K. Jr., 1968: Dehydrogenases in the rat ovary. II. A histochemical study of steroid and carbohydrate metabolising enzymes in micropolycystic ovaries induced by continuous illumination. *Endocrinology*, **83**: 329–335.
- GURAYA S. S., 1985: *Biology of Ovarian Follicles in Mammals*. Springer-Verlag, Berlin, 320 pp.
- HADJISKY P., GEORGIEWA Y. & WEGMANN R., 1969: Etudes cyto-enzymatiques de l'ovaire de la ratte durant l'ontogenese et le cycle oestral. Enzymes du metabolisme enegetique. *Ann. Histochem.*, **14**: 19–32.
- JAROLI D. P., 1980: *Seasonal histoenzymological and histochemical alterations in the ovary and uterus of Indian micro- and megachiropteran Mammals*. Unpubl. Ph.D. Thesis, University of Udaipur, 216 pp.
- LALL S. B., 1986: Folliculogenesis in *Rhinopoma kinneari* Wroughton (Microchiroptera: Mammalia). *Myotis*, **23–24**: 37–44.
- MAYNER D. A., 1966: Enzymatic histochemistry of the ovary, testis and epididymis of the fetal pig. *Anat. Rec.*, **154**: 384.
- PEARSE A. G. E., 1972: *Histochemistry: Theoretical and Applied. Vol. II. 3rd Edition*. Churchill Ltd., Edinburgh, 1518 pp.
- TRIVEDI S., 1991: *Seasonal histochemical and histoenzymological alterations in the ovary and uterus of certain chiroptera (Mammalia) of Rajasthan*. Unpubl. Ph.D. Thesis. ML Sukhadia University, Udaipur, 227 pp.
- WIMSATT W. A., 1979: Reproductive asymmetry and unilateral pregnancy in Chiroptera. *J. Reprod. Fertil.*, **56**: 345–357.

received 4. 5. 2003